

IN BRIEF:

Topics in Pediatric Orthopedics

Managing Pediatric Physeal Ankle Fractures

By Walter Truong, M.D., Pediatric Orthopedic Surgeon

Active, sports-minded children who are 8 to 16 years old are at risk for physeal ankle fractures, because activities like soccer, basketball, football and skateboarding require quick changes of direction. Those movements put stress on tendons, ligaments, bones and open physes (growth plates). Often, in children, the physis is the weak link in these stabilizing structures. Children under 12, whose physes have not yet begun to close, are at risk of developing complications such as growth disruption or angular deformity, and they need careful follow-up.

However, the risk of significant physeal damage decreases in teenage girls (14 to 15 years old) and boys (16 to 17 years old), because the physes close as adolescents reach skeletal maturity. What follows is a guide to assessing and managing pediatric physeal fractures.

History, Physical Exam and Imaging

In addition to getting a thorough history, examine the foot and ankle for swelling, deformity and signs of vascular, motor and sensory deficits. Focal tenderness over the bone is more typical of a fracture, while soft tissue tenderness is often more diffuse with a sprain.

According to the Ottawa Ankle Rules, AP, lateral and mortise radiographs are appropriate when the clinical exam meets these criteria: the patient cannot bear weight and is unable to take four steps during evaluation, and the exam reveals bony tenderness. A mortise radiograph may help identify a nondisplaced or minimally displaced fracture, even if no obvious deformity is seen. If follow-up radiographs are done 10 to 14 days after the injury, there may be evidence of new bone formation, which would confirm that a fracture occurred.

For intra-articular fractures, CT scans or MRIs are useful in evaluating the amount of displacement at the fracture site. CT scans provide better bony detail, while MRI scans are superior for looking at soft-tissue injuries and swelling within the bone.


Initial Treatment and Longer Term Monitoring

When making treatment decisions, consider the location and severity of the injury, classification of the fracture, patient's age and growth potential of the physis.

Salter-Harris Type I or II fractures (See Fig. 1 on back) can often be treated nonoperatively with closed reduction and casting or splinting. Usually the ankle will need to be immobilized for three to six weeks. Severely displaced fractures require reduction and possible fixation to maintain alignment (Fig. 2). Salter-Harris Type III or IV fractures call for open reduction and internal fixation, if the displacement is beyond 2 mm, due to the risk of degenerative changes at the articular surface.

With adolescent patients, if the physis has closed, treatment is complete when the bone is healed. However, younger children, whose physes remain open, should be monitored for 12 months after the injury to ensure that growth arrest, shortening or angular deformity have not occurred. These complications are less common with Salter-Harris Type I and II fractures.

Children who have fractures requiring reduction, and those whose physeal growth requires surveillance, should be referred to a pediatric orthopedic surgeon.



Walter Truong, M.D., is a pediatric orthopedic surgeon who specializes in treating children who have scoliosis, cerebral palsy, various hip pathologies or orthopedic trauma. He attended Ohio State University College of Medicine before completing his residency in orthopedic surgery at the University of Minnesota Medical School. He spent his fellowship year at the Hospital for Sick Children in Toronto, where he obtained a certificate from the University of Toronto Faculty of Medicine in pediatric orthopedic surgery. He participates in research at Gillette and through the University of Minnesota Department of Orthopedics. He has made a number of professional presentations, and he is a member of the American Academy of Orthopedic Surgeons and Pediatric Orthopedic Society of North America. He is a fellow of the Royal College of Surgeons of Canada.

Key Insights

- Activities that require quick changes of direction put stress on open physes (growth plates).
- Because younger children (girls < 12 and boys < 14) have physes that have not fully closed, they are more at risk of growth-related complications.
- Nondisplaced Salter-Harris Type I or II fractures can be treated nonoperatively with closed reduction and casting or splinting.
- More severe fractures, and Salter-Harris Type III or IV fractures, often call for open reduction and internal fixation.
- Younger children, whose physes remain open, should be monitored for 12 months after the injury to ensure that growth arrest, shortening or angular deformity has not occurred.

INSIDE:

Managing Pediatric Physical Ankle Fractures



To make a referral, call 651-325-2200 or 855-325-2200 (toll-free).

200 University Ave. E.
St. Paul, MN 55101

www.gillettechildrens.org

Editor - Paul Fiore
Writer - Ellen Shriner
Graphic Designer - Becky Wright



Copyright 2015, Gillette Children's Specialty Healthcare.

Gillette Children's Specialty Healthcare is named in honor of orthopedic surgeon Arthur Gillette, M.D., who helped found the nation's first hospital for children who have disabilities. We are an independent, not-for-profit children's hospital, and our organization has no affiliation with the Gillette Company or the Gillette brand of personal care products.

About InBrief

InBrief has been developed by pediatric orthopedic specialists at Gillette Children's Specialty Healthcare as a resource for primary care providers. If you have comments or questions, please contact Marybeth Fitzgerald, M.H.A., R.N., program manager, Center for Pediatric Orthopedics, at MFitzgerald@gillettechildrens.com.

To subscribe to or unsubscribe from InBrief, please send an email to Publications@gillettechildrens.com.

ADDRESS SERVICE REQUESTED

Salter-Harris Classification

Fig. 1

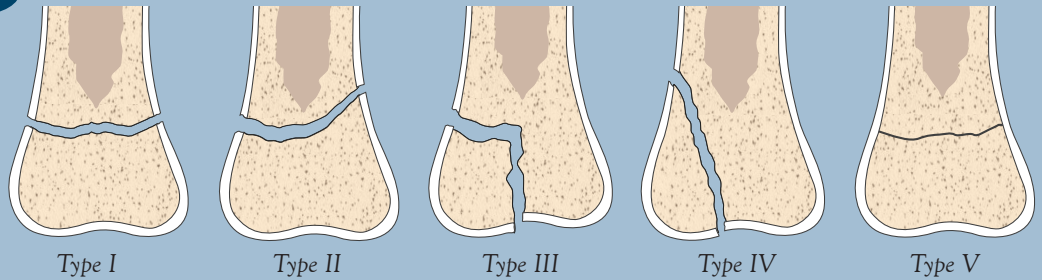
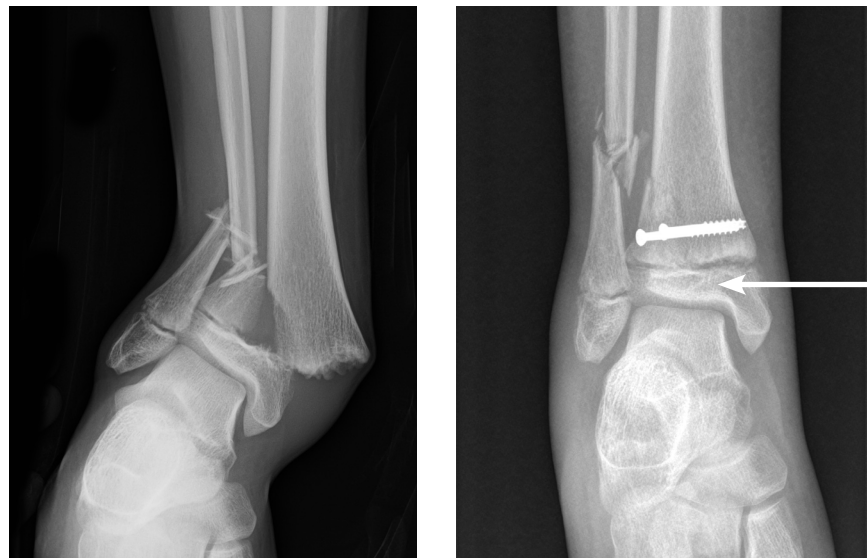

Fig. 2



Displaced Salter-Harris II fracture in a 12-year-old male.

The portion of the physis at risk for premature closure