

IN BRIEF:

Topics in Pediatric Orthopedics



Treating Clubfoot (Congenital Talipes Equinovarus)

By Benjamin Novak, M.D.
Pediatric orthopedic surgeon

Clubfoot (congenital talipes equinovarus) is a foot disorder that affects one to two people in 1,000. The condition is usually diagnosed at birth or during prenatal ultrasound screening. It is not thought to be an intrauterine packaging condition, but rather a congenital dysplasia of the musculoskeletal tissues below the knee, and it does not spontaneously correct without treatment.

Clubfoot is most often idiopathic, occurring in otherwise normal infants, but it may also be associated with neuromuscular or syndromic conditions such as arthrogryposis or myelodysplasia. It can cluster in families, but does not follow typical Mendelian inheritance patterns. Boys are more often affected than girls, and the condition occurs bilaterally in 40 to 50 percent of cases.

Diagnosis

During the physical exam, clinicians will note that the affected foot has a marked equinus (fixed plantar-flexed) contracture. The foot is inverted, giving it an almost upside-down appearance. In a true clubfoot, the abnormal position of the foot cannot be completely corrected initially. Mild clubfoot may resemble metatarsus adductus; however, metatarsus adductus does not include the equinus component. If clubfoot is suspected or clinically diagnosed, refer to a pediatric orthopedic surgeon as soon as possible.


Treatment

Historically, poor casting techniques resulted in the need for extensive surgical releases to correct clubfoot. Surgical release resulted in good short-term function, but in long-term follow-up studies, patients reported stiffness and pain. In the 1940s, Ignacio Ponseti, M.D., began refining his stretching and casting technique. His method did not gain popularity until the late 1990s, after his first long-term follow-up study was published in 1995. Currently, the Ponseti method is the accepted method for treating idiopathic clubfoot.

Ponseti Method

Treatment begins as soon as possible after the diagnosis is confirmed. The technique consists of serial stretching and casting in long-leg plaster casts. Casts are changed every five to seven days, and most clubfeet require five or six casts for correction. The equinus deformity is the last to be corrected and usually requires a percutaneous tendo-Achilles lengthening (85 percent of patients), which is performed in clinic or surgery. The affected foot is casted for three more weeks. Patients then wear an abduction orthosis for two to four years to prevent a recurrence of the deformity. Families should be educated that noncompliance with the abduction orthosis is the primary reason for recurrence.

Most patients who undergo successful clubfoot treatment will have a functional, painless foot and will not require special shoes or braces. However, it is important that patients and their families know that the calf on the clubfoot leg will always be smaller than that of the unaffected leg, and there may be an associated limb-length discrepancy. In most cases, any discrepancy will be insignificant.



Pediatric orthopedic surgeon **Benjamin Novak, M.D.**, focuses on treating conditions such as fractures, limb deformity, developmental dysplasia of the hip, clubfoot, and other bone and soft tissue conditions. He also treats patients who have a spectrum of neuromuscular disorders such as cerebral palsy.

He received his medical degree from the University of Minnesota Medical School and completed his orthopedic surgery residency at Henry Ford Health System in Detroit, Mich. He completed a pediatric orthopedic fellowship at Gillette Children's Specialty Healthcare. He is a member of the American Academy of Orthopaedic Surgeons and the Pediatric Orthopaedic Society of North America.

Key Insights

- Clubfoot (congenital talipes equinovarus) is not thought to be an intrauterine packaging condition, but rather a congenital dysplasia of the musculoskeletal tissues below the knee, and it does not spontaneously correct without treatment.
- Boys are more often affected than girls, and the condition occurs bilaterally in 40 to 50 percent of cases.
- Mild clubfoot may resemble metatarsus adductus; however, metatarsus adductus does not include the equinus component.
- The Ponseti method is the accepted method for the treatment of idiopathic clubfoot. Most patients who undergo successful clubfoot treatment will have a functional, painless foot and will not require special shoes or braces.

INSIDE:

Treating Clubfoot
(Congenital Talipes Equinovarus)



To make a referral, call
651-325-2200 or
855-325-2200 (toll-free).

200 University Ave. E.
St. Paul, MN 55101

www.gillettechildrens.org

Editor - Paul Fiore

Writer - Ellen Shriner

Graphic Designer - Kim Goodness

Photographers - Anna Bittner,
Paul DeMarchi



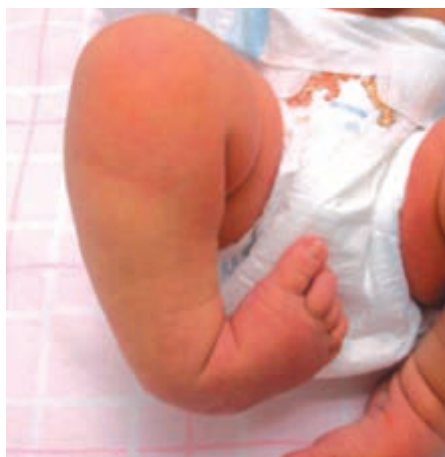Copyright 2013, Gillette Children's
Specialty Healthcare.

**ADDRESS SERVICE
REQUESTED**

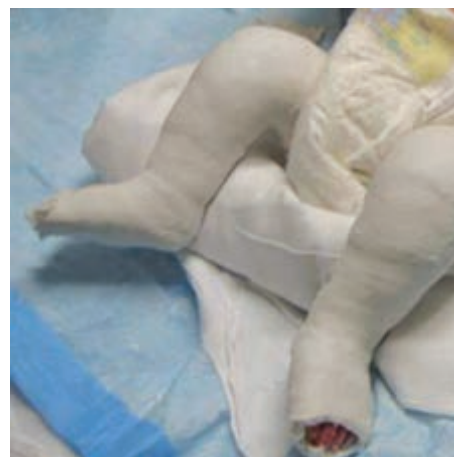Treating Clubfoot (Congenital Talipes Equinovarus)

About *InBrief*

InBrief has been developed by pediatric orthopedic specialists at Gillette Children's Specialty Healthcare as a resource for primary care providers. If you have comments or questions, please contact Paul Fiore, M.B.A., F.A.C.H.E., program manager, Center for Pediatric Orthopedics, at pfiore@gillettechildrens.com.



Infant with right clubfoot. Note the inverted position and the "upside-down" appearance of the foot.



Infant with bilateral clubfeet undergoing Ponseti casting. Patient still has equinus of the feet, which is the last component to be corrected.