

IN BRIEF:

Topics in Pediatric Orthopedics

Managing Adolescent Idiopathic Scoliosis

By Tenner Guillaume, M.D., pediatric spine surgeon

Adolescent idiopathic scoliosis is the diagnosis used to describe individuals who are 10 or older and have a spinal curve of more than 10 degrees (as seen on a radiograph). It results from a genetic abnormality; however, which genes or how many genes are involved is unknown.

Incidence

In the general population, approximately 2 to 3 percent of individuals have scoliosis. Within the population of people who have adolescent idiopathic scoliosis, only 10 percent of individuals have a curve magnitude of 30 degrees or more. Thus, in the majority of cases, scoliosis has a rather benign course.^{1,3}

Treatment Guidelines

Scoliosis alone is not a reason to initiate treatment. Aside from cosmetic concerns, adults who have untreated adolescent idiopathic scoliosis have little physical impairment and are able to function at a high level. Adults with untreated adolescent idiopathic scoliosis frequently experience back pain, but the amount of pain is no greater than that experienced by the average individual of the same age who has chronic back pain. And 68 percent⁴ of individuals who have adolescent idiopathic scoliosis and back pain reported little or moderate back pain.

The goal of scoliosis treatment is to prevent spinal curves from becoming large. A 70- to 80-degree curve can compromise lung function, and a 100-degree curve can lead to compromised heart function. Therefore, when we are treating scoliosis, we are trying to take individuals with an acceptable state of health and prevent them from ever reaching an unacceptable state of health because of their scoliosis. Most at risk are younger or skeletally immature adolescents whose spinal curves are progressing and have the potential to reach higher degrees of magnitude.

If the curvature is more than 30 degrees, we use bracing to minimize the risk of curve progression and, potentially, to avoid surgery. Of note, bracing is an effective treatment only for skeletally immature individuals. For most girls, skeletal maturity occurs between ages 13 and 16, and most boys reach skeletal maturity between 15 and 18. Bracing is no longer indicated once patients are skeletally mature.

Generally, we stabilize curves of greater than 50 degrees surgically with a posterior instrumented spinal fusion. Curves greater than 50 degrees, in individuals who have not yet reached skeletal maturity, progress at a rate of about one degree per year.

During spinal fusion, we straighten a curved spine as much as we safely can and then keep the curve locked in that position for life. Although this procedure stiffens the spine, there is no intervention that allows for both straightening the spine and maintaining motion of the spine. With spine fusion surgery, we balance spine stiffness against long-term control of deformity progression, prevention of heart or lung issues, and minimization of potentially significant pain associated with large magnitude deformity.

References

- ¹ Kane WJ. Scoliosis Prevalence: A call for a statement of terms. *Clin Orthop* 1977, 126: 43-46.
- ² Robin GC. The Etiology of Idiopathic Scoliosis. Boca Raton, FL; CRC Press; 1990: 43-60.
- ³ Nissinen M, Heliövaara M, Ylikoski M, Poussa M. Trunk asymmetry and screening for scoliosis: A longitudinal cohort study of pubertal schoolchildren. *Acta Paediatr* 1993, 82: 77-82.
- ⁴ Weinstein SL, Dolan LA, Spratt KF, Peterson KK, Spoonamore MJ, Ponseti IV. Health and Function of Patients with Untreated Idiopathic Scoliosis: A 50-Year Natural History Study. *JAMA* 2003, 289(5): 559-567.



Tenner Guillaume, M.D., is a board-certified orthopedic surgeon who specializes in spine surgery. His professional interests include management of pediatric congenital and idiopathic scoliosis as well as isthmic spondylolisthesis. He received his medical degree from the University of Minnesota Medical School. He completed an internship and residency at the University of California – San Francisco Medical Center and a spine surgery fellowship through the Twin Cities Spine Center in Minneapolis. He has presented research, posters and abstracts, and he has professional publications. He is a member of the American Academy of Orthopaedic Surgeons and the North American Spine Society. He is a candidate for membership in the Scoliosis Research Society and the Pediatric Orthopaedic Society of North America.

Key Insights

- In the general population, approximately 2 to 3 percent of individuals have scoliosis. Only 10 percent of individuals with adolescent idiopathic scoliosis have a curve magnitude of 30 degrees or more.^{1,3}
- The goal of scoliosis treatment is to prevent spinal curves from becoming large enough to compromise lung or heart function.
- Bracing is used for skeletally immature patients whose curve is more than 30 degrees.
- For patients who have curves that are greater than 50 degrees, posterior instrumented spinal fusion is appropriate.

INSIDE:

Managing Adolescent Idiopathic Scoliosis



To make a referral, call 651-325-2200 or 855-325-2200 (toll-free).

200 University Ave. E.
 St. Paul, MN 55101
 651-325-2200 or 855-325-2200 (toll-free)
 www.gillettechildrens.org

Editor - Paul Fiore
 Writer - Ellen Shriner
 Graphic Designer - Kim Goodness
 Photographers - Anna Bittner,
 Paul DeMarchi



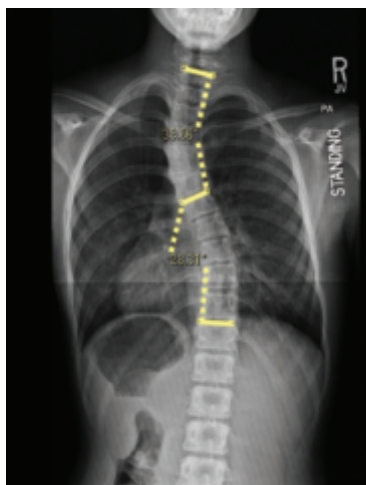
Copyright 2013, Gillette Children's Specialty Healthcare.

**ADDRESS SERVICE
 REQUESTED**

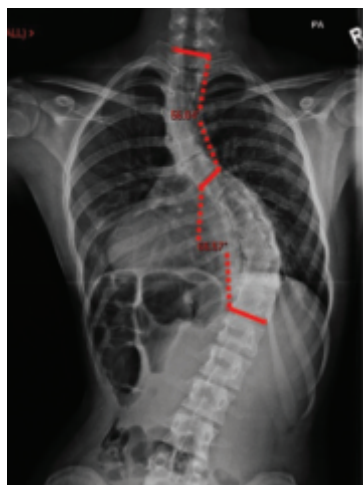Managing Scoliosis

About *InBrief*

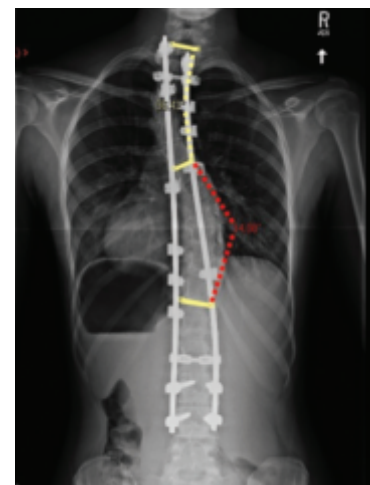
InBrief has been developed by pediatric orthopedic specialists at Gillette Children's Specialty Healthcare as a resource for primary care providers. If you have comments or questions, please contact Paul Fiore, M.B.A., F.A.C.H.E., program manager, Center for Pediatric Orthopedics, at pfiore@gillettechildrens.com.



At initial presentation, this 13-year-old girl had a 28 degree apex right thoracic curve and a 38 degree apex left upper thoracic curve. Given her curve size and skeletal immaturity, a brace was recommended.



Although the brace slowed the curve progression, the patient's curve had progressed significantly by the time she was 16. Because she had a 62 degree right thoracic curve and a 57 degree left upper thoracic curve, surgery was recommended.



At her one-year postoperative check-up, the patient's curve is stable and she had returned to her preoperative level of function.